

# What is Central Serous Chorioretinopathy?

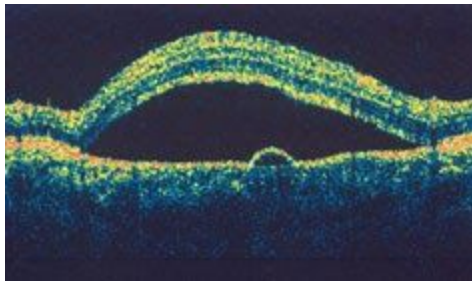
Central serous chorioretinopathy is when fluid builds up under the [retina](#). This can distort vision. The fluid leakage comes from a layer of tissue under the retina, called the [choroid](#). The layer of cells between the retina and choroid is called the retinal pigment epithelium (RPE). When RPE does not work as it should, fluid builds up under the retina or the RPE resulting in a small detachment and visual distortion.

Central serous chorioretinopathy usually affects just one eye at a time, but both eyes can be affected at the same time.

## Central serous chorioretinopathy symptoms

Symptoms of central serous chorioretinopathy can include:

- distorted, dimmed, or blurred central vision
- a dark area in your central vision
- straight lines may appear bent, crooked or irregular in your affected eye
- objects may appear smaller or further away than they are
- when you look at a white object, it may appear to have a brownish tinge or appear duller in color



*This image from an OCT scan shows how central serous retinopathy (also called central serous chorioidopathy) causes a blister-like swelling in layers of the retina.*

## Who is at risk for central serous chorioretinopathy?

Men in their 30s to 50s are more likely to develop central serous chorioretinopathy than women. Stress is a major risk factor. People under a lot of stress may be more likely to develop central serous chorioretinopathy.

Other risk factors for central serous chorioretinopathy are:

- use of steroids (by mouth, through a vein or even inhaled)
- *Helicobacter pylori* infection (a type of bacteria that can infect the stomach)

- autoimmune disease (when the body attacks its own tissues)
- sleep disturbances like insomnia (having trouble falling asleep or staying asleep) or sleep apnea (when breathing is interrupted during sleep)
- type A behavior (aggressive and competitive behavior)
- [hypertension \(high blood pressure\)](#)

Source: <https://www.aao.org/eye-health/diseases/what-is-central-serous-retinopathy>